



E-ISSN: 2663-2268
P-ISSN: 2663-225X
IJARMSN 2022; 4(2): 62-67
Received: 25-04-2022
Accepted: 30-05-2022

I Sharon Shiney Paul
Nurse Educator Sri
Ramakrishna Hospital,
Coimbatore, Tamil Nadu,
India

Case report on Stevens - Johnson syndrome

I Sharon Shiney Paul

Abstract

Stevens-Johnson syndrome (SJS) is a hypersensitivity reaction that affects the skin and mucous membranes. In this case report the patient had drug induced hypersensitivity reaction after taking treatment for bilateral leg edema, was hospitalized and later diagnosed as SJS. Upon evaluation, the patient had increased serum creatinine, decreased albumin, decreased urinary output almost anuric and bilateral leg edema which are the signs of acute kidney injury (AKI), a common complication of SJS/TEN. The patient was treated with fluid replacement, wound dressing, Incision and drainage of abscess in left thigh and leg, Necrotic patches were removed by wound debridement. Further the patient needed split skin graft for left leg and thigh but due to her age and general condition, the surgery was deferred. She was discharged with the follow up advice.

Keywords: Stevens - Johnson syndrome, toxic epidermal necrolysis, acute kidney injury

Introduction

An uncommon and severe skin condition called SJS, which is caused by medications, infections, vaccinations, and graft-versus-host disease, affects both the skin layers and mucous membrane. SJS was first described in 1922 by the physicians Albert Mason Stevens and Frank Chambliss Johnson who evaluated the symptoms of an unknown condition in two young boys and published a report about this condition in the American Journal of Diseases of Children, hence the disease was named after them as Stevens-Johnson syndrome.

The symptoms of Toxic Epidermal Necrolysis (TEN) is very similar to SJS and they are classified based on the severity in the disease spectrum. Experts consider SJS less severe than TEN.

Case history

An 85-year-old female was admitted in a private hospital with the complaints of skin lesion on left lateral and medial side of leg and thigh for 7 days. There was a history of bilateral leg edema intermittently for a year. Patient initially went to nearby hospital for leg swelling and took Tab. Pantoprazole, Tab. Domperidone, Tab. Torsemide 10 mg, and Cap. Probiotics, Tab. Acelofenac 500mg and Azulix oil for 2 days following which the symptoms developed. On investigation, patient had Blood sugar of 230 mg/dL, Serum Creatinine 1.3 mg/dL, Albumin 1.7 gm/dl, Hemoglobin 6.6 g/dL. Had decreased urinary output almost anuric while in the hospital, Intake and output monitored. The wound culture revealed heavy growth of microorganism. Venous Doppler study of left lower limb showed partial thrombus with good recanalization are seen in bilateral common femoral, right superficial femoral and profunda veins. After thorough investigations, she was diagnosed with Stevens Johnson syndrome, Anemia, Hypoalbuminemia, Acute kidney injury. Patient was treated with Inj. Polymyxin B (7.5 lakh IU), Cap. Doxycycline (100 mg). Supportive care like fluid replacement, wound dressing was provided.

Also underwent Incision and drainage of abscess in left thigh and leg under spinal anesthesia. Necrotic patch over the left thigh and leg was excised and wound debridement done. Patient needed Split skin graft for left leg and thigh, since her general condition was poor, hypoalbuminemia and anuric; surgery was deferred

Definition

SJS is a hypersensitivity reaction that typically involves the skin and the mucous membranes. SJS/TEN is also known as Lyell syndrome.

Corresponding Author:
I Sharon Shiney Paul
Nurse Educator Sri
Ramakrishna Hospital,
Coimbatore, Tamil Nadu,
India

Incidence

SJS/TEN is a rare disease that affects less than 7 people in a million population each year. SJS/TEN can affect at any age, either sex or all race, but more common in older people and women. Patients with HIV infection is affected more with an estimated incidence of 1/1000.

Etiology

1. Medications Like
 - Anti-gout medications especially Allopurinol.
 - Analgesics such as Acetaminophen, Ibuprofen and Naproxen Sodium.
 - Sulfa Antibiotics, which are common cause in kids
 - Anti-seizure drugs especially Carbamazepine.
 - Anti-psychotics.
2. Infection like Pneumonia, Hepatitis A or Herpes virus.
3. Graft-versus-host disease.
4. Previous history of SJS.
5. Family history of SJS.
6. Radiation treatments.
7. Vaccinations.

Risk factors

Factors that increase your risk of developing SJS include:

- Bone marrow transplant.
- Systemic lupus erythematosus.
- Human Immunodeficiency Virus.
- Other chronic diseases of joint and connective tissue.

- Cancer.
- Variation of specific gene called human leukocyte antigen-B.

Classification

The classification of the disease is based on the total body surface area (BSA) involved with skin detachment:

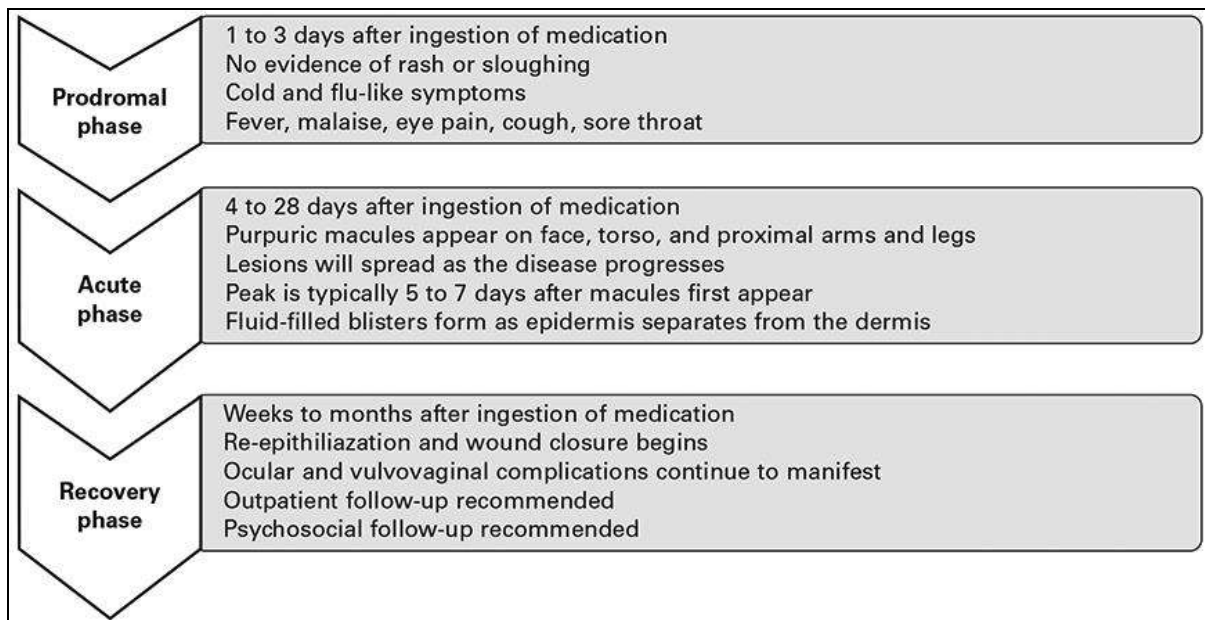
- SJS - affects < 10 % of BSA
- TEN - affects > 30 % of BSA
- SJS/TEN overlap – affects 10 to 30 % of BSA

Clinical manifestation

The manifestation begins with flu-like symptoms, progresses to lesions, rashes, blisters, and then, after several days, the affected skin sheds and starts to heal. It may also damage the mucous membranes that line the mouth, eyes, and genitalia, making it extremely difficult to eat, swallow, and urinate.

The prodromal symptoms start within 1 to 3 weeks after intake of the offending drug

- Cough productive of a thick, purulent sputum.
- Headache.
- Malaise.
- Fever > 39 °C.
- Arthralgia.
- Kerato conjunctivitis.
- Sore throat and difficulty in swallowing.



Other manifestation includes

- Macules that appear usually on the face, neck, and upper trunk, then coalesce into large flaccid bullae, and slough over a period of 1 to 3 days.
- Nails, eyebrows, palms and soles along with epithelium will be affected.
- Skin, mucosal, and eye pain.
- Diffuse erythema is the first skin abnormality in some case of TEN.
- In severe cases of TEN, large sheets of epithelium slide off at pressure points (Nikolsky sign).
- In up to 90 % of instances, the symptoms are accompanied by uncomfortable oral crusts and erosions, keratoconjunctivitis, and genital issues (such

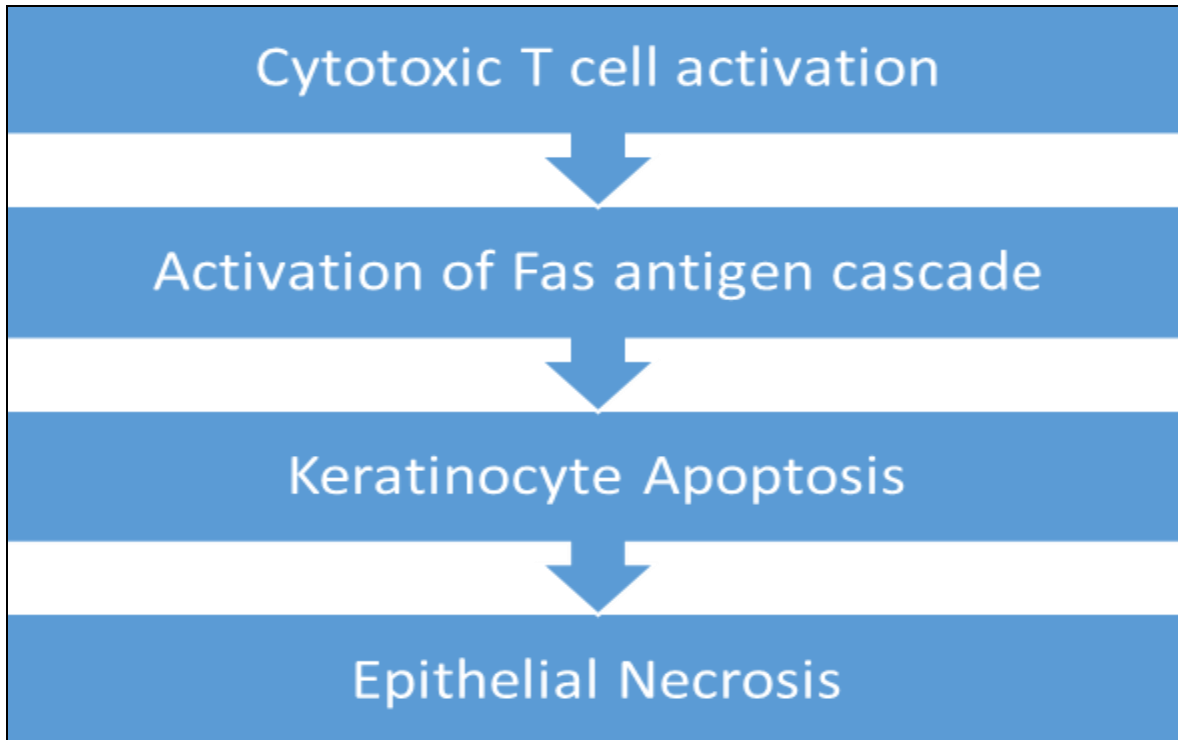
- as urethritis, phimosis, and vaginal synechiae).
- Additionally, the bronchial epithelium may shed, leading to the development of cough, dyspnea, pneumonia, pulmonary edoema, and hypoxemia.
- Glomerulonephritis and hepatitis may develop.

Pathophysiology

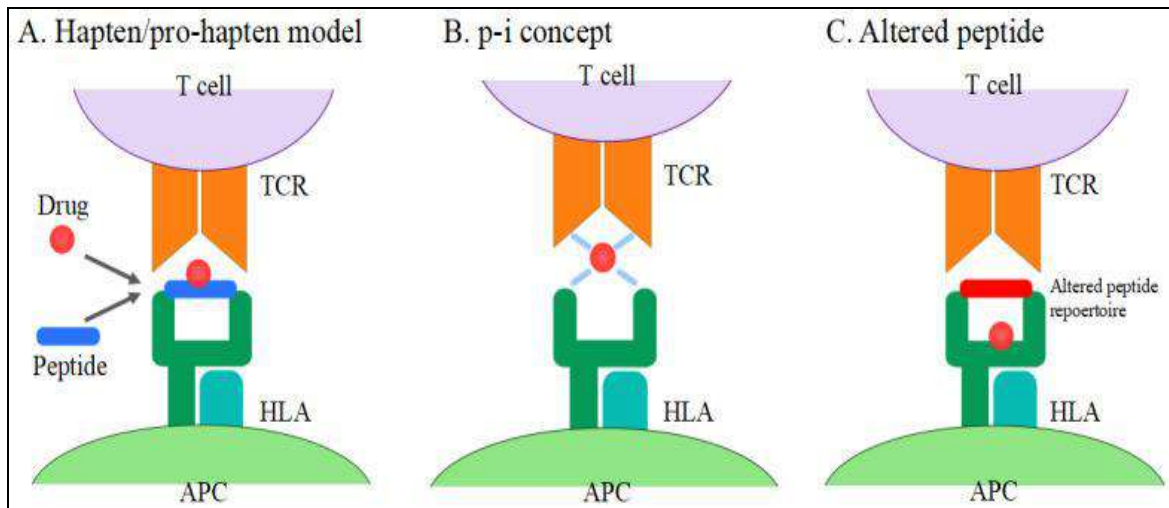
The pathophysiology of SJS/TEN is complicated. A number of theories have proposed both immunological and non-immunological processes, although the preponderance evidence suggesting those mediated by memory cytotoxic T cells. The Fas antigen, a cell surface protein that can trigger apoptosis, starts the SJS reaction. Epithelial necrosis and extensive keratinocyte death are caused by the activation of

the Fas signaling cascade. Early intravenous immunoglobulin (IVIg) therapy for SJS prevents the

activation of the Fas pathway, highlighting the potential benefit of IVIg for the treatment of the condition.



T-cell activation model



- a. **The hapten/pro-hapten model:** In the peptide-binding groove of the Human Leukocyte Antigen (HLA) molecules, drug metabolites bind to carrier proteins as haptenated peptides to create a complex.
- b. **P-I Concept:** medicines attach non-covalently and directly to HLA and T-Cell Receptor (TCR).
- c. **Modified peptide model:** Drugs that bind to the HLA's peptide-binding groove change the peptide repertoire that binds to HLA.

SJS. The onset of SJS may be influenced by genetic factors. The risk of developing SJS is thought to be higher in patients with modest intrinsic acetylation rates and those taking drugs including azoles, protease inhibitors, serotonin-specific reuptake inhibitors, and quinolones. As the slowed rate of acetylation results in the accumulation of reactive metabolites that trigger cell-mediated cytotoxic responses targeted against target cells, slow acetylation may indeed play a role in the development of a number of adverse cutaneous drug reactions.

Diagnostic evaluation:

- Thorough history collection and Physical evaluation
- Skin biopsy
- Elevated levels of serum granulysin taken in the first

Perforin, a monomeric granule produced from natural killer T cells, has been connected in studies to the onset of SJS. The keratinolysis found early in the development of SJS is thought to have been started by perforin. There is some evidence supporting the idea that mast cell activation and IgE-mediated pathways both contribute to

few days of a drug eruption may be predictive of SJS/TEN.

- Histopathology shows keratinocyte necrosis, full thickness epidermal/epithelial necrosis, minimal inflammation.

Blood tests do not help to make the diagnosis but are essential to replace fluid and vital nutrients, to identify complications and to assess prognostic factors. Abnormalities may include

- Anaemia
- Leucopenia
- Neutropenia indicates bad prognostic sign
- Mildly raised liver enzymes and approximately 10% develop overt hepatitis.
- Mild proteinuria and some changes in kidney function

Scortten score

In order to forecast mortality in SJS and TEN cases, the sickness severity index known as SCORTEN was created. Each of the seven requirements that were met at the time of admission is worth one point. The SCORTEN criteria are:

- Age > 40 years.
- Presence of malignancy (cancer).
- Heart rate > 120.
- Initial percentage of epidermal detachment > 10 %.
- Serum urea level > 10 mmol/L.
- Serum glucose level > 14 mmol/L.
- Serum bicarbonate level < 20 mmol/L.

The risk of dying from SJS/TEN depends on the score

- SCORTEN 0-1 > 3.2 %.
- SCORTEN 2 > 12.1 %.
- SCORTEN 3 > 35.3 %.
- SCORTEN 4 > 58.3 %.
- SCORTEN 5 or more > 90 %.

In 2019, A new prediction model was proposed, the ABCD-10

A: age over 50 years (one point).

B: bicarbonate level < 20 mmol/L (one point).

C: cancer present and active (two points).

D: dialysis prior to admission (3 points).

10: epidermal detachment \geq 10 % body surface area on admission (one point)

Management

Care of a patient with SJS/TEN requires

- Cessation of suspected causative drug(s)
- Hospital admission — to an intensive care and burns unit with specialist nursing care, as this improves survival, reduces infection and shortens hospital stay
- Consider fluidised air bed
- Nutritional and fluid replacement (crystalloid) by intravenous and nasogastric routes — reviewed and adjusted daily
- Temperature maintenance — as body temperature regulation is impaired, the patient should be in a warm room (30–32 °C).
- Pain relief — as pain can be extreme
- Sterile handling and reverse isolation procedures.

Skin care

- Examine daily for the extent of detachment and

infection (take swabs for bacterial culture).

- Topical antiseptics can be used (e.g., silver nitrate, chlorhexidine [but not silver sulfadiazine as it is a sulfa drug]).
- Dressings such as gauze with petrolatum, non-adherent nanocrystalline-containing silver gauze or biosynthetic skin substitutes such as Biobrane can reduce pain.
- Avoid using adhesive tapes and unnecessary removal of dead skin; leave the blister roof as a 'biological dressing'.

Other supportive care includes

- Psychiatric support for extreme anxiety and emotional lability.
- Physiotherapy to maintain joint movement and reduce the risk of pneumonia.
- Regular assessment for staphylococcal or gram negative infection.
- The appropriate antibiotic should be given if an infection develops; prophylactic antibiotics are not recommended and may even increase the risk of sepsis
- Consider heparin to prevent thromboembolism.
- Pain management.
- Respiratory support.
- Eye care.
- Genital care.

Medical management

- Ciclosporin 3-5 mg/kg/day is reported to reduce mortality by 60% compared to patients with similar SCORTEN score on admission that were not treated with cyclosporine. There are contraindications to treatment such as renal impairment.
- Anti-TNF α monoclonal antibodies (e.g., infliximab, etanercept).
- Cyclophosphamide.
- Intravenous immunoglobulin (IVIG) 2-3 g/kg given over 2-3 days.
- Granulocyte-colony stimulating factor (G-CSF).
- Use of Systemic Corticosteroids (cortisone) remains controversial, but sometimes high doses of corticosteroids at the start of the reaction, usually prednisone 1-2 mg/kg/day for 3-5 days.
- Plasmapheresis

Complications

During the acute phase, potentially fatal complications include

- Dehydration and acute malnutrition.
- Infection of skin, mucous membranes, lungs (pneumonia), septicaemia (blood poisoning).
- Acute respiratory distress syndrome.
- Gastrointestinal ulceration, perforation and intussusception.
- Shock and multiple organ failure including kidney failure.
- Thromboembolism and disseminated intravascular coag ulopathy.
- Death.
- Acute Kidney Injury.

Differential diagnosis

In the differential diagnosis of SJS/TEN consider:

- Other severe cutaneous adverse reactions (SCARs) to

drugs (e.g., drug hypersensitivity syndrome).

- Staphylococcal scalded skin syndrome and toxic shock syndrome.
- Erythema multiform, particularly erythema multiform major (with mucosal involvement).
- Mycoplasma infections.
- Bullous systemic lupus erythematosus.
- Paraneoplastic pemphigus.
- Toxic shock syndrome Exfoliative erythroderma.

Prevention

- Patient must be educated to avoid taking causative drug or related medicines to avoid reoccurrence.
- The cross-reactions can occur between medications like anticonvulsants, Antibiotics, NSAIDs and Sulfonamides.
- In the future, advancement in genetic screening may be help to predict who is at risk of SJS/TEN
- Allopurinol should be prescribed for good indications (e.g., gout with hyperuricaemia) and commenced at a low dose (100 mg/day), as SJS/TEN is more likely at doses > 200 mg/day.

Conclusion

SJS can present as a severe cutaneous reaction to medications, within the first month of treatment. Initial symptoms include diffuse erythema, blisters, shortness of breath, and conjunctivitis. Rapid diagnosis and treatment of SJS are critical, to avoid its progress to shock and multiple organ failure. This case report highlights disparities in medical education of SJS, initiate quick response in diagnosis, providing appropriate supportive therapy and to preventable life-threatening conditions.

References

1. Akito Hasegawa, Riichiro Abe, Recent advances in managing and understanding Stevens-Johnson syndrome and Toxic Epidermal Necrolysis; c2020 Jun 16. <https://pubmed.ncbi.nlm.nih.gov/32595945/>
2. Robert Frantz. Stevens - Johnson syndrome and Toxic Epidermal Necrolysis: A Review of Diagnosis and management; c2021 Aug 28. <https://pubmed.ncbi.nlm.nih.gov/34577817/>
3. Lucia Liotti, Clinical features, outcome and treatment in children with drug induced Stevens-Johnson syndrome and toxic epidermal necrolysis. *Acta Bio Medica: Atenei Parmensis*. 2019;90(Suppl 3):52, <https://pubmed.ncbi.nlm.nih.gov/30830062/>
4. Leah M Hanson. Stevens-Johnson syndrome and Toxic epidermal necrolysis: A guide for nurses; c2020 Sep 15, <https://pubmed.ncbi.nlm.nih.gov/32866260/>
5. Amanda M Oakley, Karthik Krishnamurthy. Stevens Johnsons syndrome. *National library of medicine*; c14 April 2022. <https://www.ncbi.nlm.nih.gov/books/NBK459323/>
6. Stevens Johnsons Syndrome. *NHS*; c21 June 2022. <https://www.nhs.uk/conditions/stevens-johnson-syndrome/>
7. Stevens Johnsons Syndrome. *Cleveland Clinic*; c18 December 2020. <https://my.clevelandclinic.org/health/diseases/17656-stevens-johnson-syndrome>
8. Stevens Johnsons Syndrome. *Mayo Clinic*; c30 April 2022. [https://www.mayoclinic.org/diseases-conditions/stevens-johnson-syndrome/symptoms-causes/syc-20355936#:~:text=Stevens%20Johnson%20syndrome%20\(SJS\),rash%20that%20spreads%20and%20blisters.](https://www.mayoclinic.org/diseases-conditions/stevens-johnson-syndrome/symptoms-causes/syc-20355936#:~:text=Stevens%20Johnson%20syndrome%20(SJS),rash%20that%20spreads%20and%20blisters.)
9. Rath, Linda. Stevens Johnsons Syndrome. *WebMD*; c17 May 2021. <https://www.webmd.com/skin-problems-and-treatments/stevens-johnson-syndrome>
10. Tao Han Lee, *et al*. The influence of acute kidney injury on the outcome of SJS and TEN: the prognostic value of KDIGO staging". *National Library of Medicine*; c7 Sep 2018. [https://www.ncbi.nlm.nih.gov/pmc/articles/PMC6128626/#:~:text=Stevens%20Johnson%20syndrom%20\(SJS\),in%20patients%20with%20SJS%20FTEN.](https://www.ncbi.nlm.nih.gov/pmc/articles/PMC6128626/#:~:text=Stevens%20Johnson%20syndrom%20(SJS),in%20patients%20with%20SJS%20FTEN.)
11. Foster C Stephen. Stevens-Johnson Syndrome". *Medscape*; c17 Jan 2019. <https://emedicine.medscape.com/article/1197450-overview>
12. Benedetti, Julia Stevens-Johnson syndrome and Toxic Epidermal Necrolysis. *MSD Manual*; cSep 2022. <https://www.msmanuals.com/en-in/professional/dermatologic-disorders/hypersensitivity-and-reactive-skin-disorders/stevens-johnson-syndrome-sjs-and-toxic-epidermal-necrolysis-ten>
13. Vanessa Ngan, *et al*. Stevens-Johnson Syndrome/Toxic epidermal necrolysis. *Derm Net*; cJan 2016. <https://dermnetnz.org/topics/stevens-johnson-syndrome-toxic-epidermal-necrolysis>
14. Haur Yueh Lee. Stevens - Johnson syndrome and Toxic epidermal necrosis: management, prognosis and long-term sequelae. *Up to Date*, 31 May 2022. <https://www.uptodate.com/contents/stevens-johnson-syndrome-and-toxic-epidermal-necrolysis-management-prognosis-and-long-term-sequelae>
15. Dr. Elise Ouedraoge. Stevens-Johnson syndrome/Toxic epidermal necrolysis: nursing management. *Derm Net*; cJan 2018. <https://dermnetnz.org/topics/sjs-ten-nursing>
16. Owen Kramer MD. What is Stevens-Johnson syndrome?. *Medical News Today*; c8 Oct 2019. <https://www.medicalnewstoday.com/articles/326587>
17. Darragh O'Carroll MD. Stevens-Johnson syndrome overview. *Skin Care*; c29 Apr 2022. <https://www.healthline.com/health/stevens-johnson-syndrome>
18. Julia Benedetti MD. Stevens - Johnson syndrome and Toxic epidermal necrolysis. *MSD Manual*; cSep 2022. <https://www.msmanuals.com/en-in/home/skin-disorders/hypersensitivity-and-reactive-skin-disorders/stevens-johnson-syndrome-sjs-and-toxic-epidermal-necrolysis-ten>
19. Robert Frantz, *et al*. Stevens-Johnson syndrome and Toxic epidermal necrolysis: A review of diagnosis and management. *Medicina*; c28 Aug 2021. <https://www.mdpi.com/1648-9144/57/9/895>
20. James GH, Dinulos MD. Hypersensitivity syndrome and Vasculitis. *Science Direct*; c2021. <https://www.sciencedirect.com/topics/medicine-and-dentistry/stevens-johnson-syndrome>
21. RibhiHazin, *et al*. Stevens Johnson syndrome: Pathogenesis, diagnosis and management. *Taylor and Francis Online*; c08 July 2009. <https://www.tandfonline.com/doi/full/10.1080/07853890701753664>
22. Michelle Llamas. Stevens - Johnson syndrome.

- Drugwatch; c22 July 2022.
<https://www.drugwatch.com/health/rash-and-skin-disorders/stevens-johnson-syndrome/>
23. Stanley Oiseth, *et al.* Stevens-Johnson syndrome. Lecturi; c08 Sep 2022.
<https://www.lecturio.com/concepts/stevens-johnson-syndrome/>
24. Jay W, Marks MD. Definition of Stevens-Johnson syndrome. RxList; c06 Mar 2021.
25. https://www.rxlist.com/stevens-johnson_syndrome/definition.html
26. Hiroaki Azukizawa. Graft-versus-host disease: A model of Stevens-Johnson syndrome and Toxic epidermal necrolysis. Bentham Science. 2014;10:1.
<http://www.eurekaselect.com/article/60870>
27. Dr. Subhan Iqbal. Steven Johnson syndrome. Radiopaedia; c10 Dec 2020.
<https://radiopaedia.org/articles/stevens-johnson-syndrome>
28. Swapna S Shanbhag, *et al.* Multidisciplinary care in Stevens Johnson syndrome. Sage Journals; c28 Apr 2020.
<https://journals.sagepub.com/doi/full/10.1177/2040622319894469>
29. Darlene Diep, *et al.* Stevens - Johnson syndrome in a patient of color: A case report and an assessment of diversity in medical education resources. Cureus; c15 Feb 2022. <https://www.cureus.com/articles/87093-stevens-johnson-syndrome-in-a-patient-of-color-a-case-report-and-an-assessment-of-diversity-in-medical-education-resources>